

## RESEARCH ARTICLE

# Epidemiological Trends of Histopathologically WHO Classified CNS Tumors in Developing Countries: Systematic Review

Ishaq Khan<sup>1</sup>, Mohammed Bangash<sup>2</sup>, Saleh Baeesa<sup>2</sup>, Awatif Jamal<sup>3</sup>, Angel Carracedo<sup>4</sup>, Fahad Alghamdi<sup>3</sup>, Hanadi Qashqari<sup>5</sup>, Adel Abuzenadah<sup>6</sup>, Mohammed AlQahtani<sup>1</sup>, Ghazi Damanhour<sup>5</sup>, Adeel Chaudhary<sup>1</sup>, Deema Hussein<sup>5\*</sup>

### Abstract

**Background:** Many developing countries are lagging behind in reporting epidemiological data for individual central nervous system (CNS) tumors. This paper aimed to elicit patterns for the epidemiology of individual World Health Organization (WHO) classified CNS tumors in countries registered by WHO as “developing”. **Materials and Methods:** Cyber search was carried out through 66 cancer networks/registries and 181 PubMed published papers that reported counts of CNS tumors for the period of 2009-2012. The relationship between the natural log of incidence Age Standardized Rate (ASR) reported by Globocan and Latitude/ Longitude was investigated. **Results:** Registries for 21 countries displayed information related to CNS tumors. In contrast trends for classified CNS tumor cases were identified for 38 countries via 181 PubMed publications. Extracted data showed a majority of unclassified reported cases [PubMed (38 countries, 45.7%), registries (21 countries, 96.1%)]. For classified tumors, astrocytic tumors were the most frequently reported type [PubMed (38 countries, 1,245 cases, 15.7%), registries (21 countries, 627 cases, 1.99%)]. A significant linear regression relationship emerged between latitudes and reported cases of CNS tumors. **Conclusions:** Previously unreported trends of frequencies for individually classified CNS tumors were elucidated and a possible link of CNS tumors occurrence with geographical location emerged.

**Keywords:** CNS tumors - epidemiology - developing countries - cancer registries - latitude - risk factors

*Asian Pac J Cancer Prev*, 16 (1), 205-216

### Introduction

Eliciting patterns for the distribution of disease between different populations over time is important for the development and the realization of health policies (Chauvin et al., 2012). For tumors originating in the Central Nervous System (CNS), there is a collection of a large spectrum of neoplasms classified by World Health Organization (WHO), with each tumor having its own features, location, morphology, prognosis and treatment (DeAngelis, 2001; Louis et al., 2007; Katchy et al., 2011).

The latest Globocan report for 2012 estimated a total incidence ASR of 3.4 per 100,000 and a mortality ASR of 2.5 per 100 000 worldwide (Parkin et al., 2001; GLOBOCAN, 2014). Incidence ASR of CNS tumors in the developing region was estimated to be 3.0 per 100,000, and for mortality ASR the estimation was 2.2 per 100,000. In addition, Globocan described gender-related data and showed that men have a higher CNS tumors incidence ASR 3.9 compared with women 3.0 worldwide. Unfortunately, however, trends for individually classified types of CNS tumors are not available from this database.

Many developed countries across the globe have developed cancer registries, which record and provide data of CNS tumors' specific incidences and mortalities (Surawicz et al., 1999; CancerResearchUK, 2013a; Villano et al., 2013; Woehrer, 2013). Recent reports show that Astrocytomas were the most common in the UK (CancerResearchUK, 2013b), Meningiomas were most reported in the USA (Dolecek et al., 2012) and glioblastoma multiform (GBM) tumors had the highest frequencies in Canada (BrainTumourFoundation, 2013).

Developing countries are lagging behind in reporting epidemiological data for cancer (Ferlay et al., 2010; Qaddoumi et al., 2011). In addition, although there are cancer registries for some developing countries, they inadequately report data for different types of CNS tumors (AFCRN, 2013). To obtain an estimated perspective of the current status of CNS tumors in developing countries, detailed and global epidemiological studies are required (Katchy et al., 2011). This work aimed to elicit patterns for the epidemiology of individually reported CNS tumors subtypes in countries registered by the WHO as “developing”.

<sup>1</sup>Center of Excellence in Genomic Medicine, <sup>2</sup>Division of Neurosurgery, <sup>3</sup>King Fahd Medical Research Center, <sup>4</sup>Centre of Innovation for Personalized Medicine, King Abdulaziz University, Jeddah, Saudi Arabia, <sup>5</sup>Fundacion Galega de Medicina Xenomica (SERGAS), CIBERER-Universidade de Santiago de Compostela, Santiago de Compostela, Spain \*For correspondence: deemah@hotmail.com

**Materials and Methods***Search Strategy and Data Extraction*

Cyber methods of search strategies were implemented

to retrieve data for the incidence of CNS tumors between the years 2009-2012 in 149 countries registered by WHO as “developing” (Figure 1). Briefly, for cancer registries/networks search, Google website was searched to find

**Table 1. A list of Countries who Reported CNS Tumor Cases Via Cancer Registries or PubMed and the Predominant Tumor Types**

Region Country	Reported in Cancer Registry			Reported in PubMed		
	No. of Cases Total (%)	Predominant Tumors Type	No. of cases (%)	No. of Cases Total (%)	Predominant Tumors Type	No. of cases (%)
<b>EAP</b>						
China	NR	NR	NR	685 (8.66)	Meningeal	180 (26.3)
Malaysia	NR	NR	NR	2 (0.03)	None	None
Nepal	77 (0.24)	Unclassified	77 (100)	NR	NR	NR
Thailand	117 (0.37)	Astrocytic	63 (53.8)	88 (1.11)	Gliomas	61 (69.3)
<b>ECA</b>						
Albania	381 (1.21)	Unclassified	381 (100)	NR	NR	NR
Belarus	501 (1.59)	Unclassified	501 (100)	NR	NR	NR
Bosnia & Herzegovina	299 (0.95)	Unclassified	299 (100)	30 (0.38)	Astrocytic	16 (53.3)
Bulgaria	2123 (6.73)	Unclassified	2123 (100)	2781 (35.1)	Unclassified	2508 (90.2)
Croatia	1627 (5.16)	Unclassified	1627 (100)	57 (0.72)	Astrocytic	40 (70.2)
Georgia	NR	NR	NR	495 (6.26)	Unclassified	190 (38.4)
Hungary	595 (1.89)	Unclassified	595 (100)	33 (0.42)	Astrocytic	14 (42.4)
Latvia	256 (0.81)	Unclassified	256 (100)	45 (0.57)	Gliomas	45 (100)
Lithuania	308 (0.98)	Unclassified	308 (100)	348 (4.4)	Meningeal	117 (33.6)
Moldova	174 (0.55)	Unclassified	174 (100)	NR	NR	NR
Montenegro	66 (0.21)	Unclassified	66 (100)	NR	None	None
Poland	4467 (14.1)	Unclassified	4467 (100)	73 (0.92)	Ependymal	39 (53.4)
Romania	1895 (6.01)	Unclassified	1808 (95.4)	168 (2.12)	Pituitary	142 (84.5)
Russian Federation	7377 (23.4)	Unclassified	7377 (100)	254 (3.21)	Unclassified	231 (90.9)
Serbia	2454 (7.78)	Unclassified	2454 (100)	6 (0.08)	None	None
Turkey	NR	NR	NR	242 (3.06)	Pituitary	146 (60.3)
Ukraine	7361 (23.3)	Unclassified	7361 (100)	NR	NR	NR
<b>LAC</b>						
Argentina	NR	NR	NR	29 (0.37)	Unclassified	22 (75.9)
Brazil	NR	NR	NR	38 (0.48)	Embryonal	37 (97.4)
Chile	NR	NR	NR	6 (0.08)	Pituitary	3 (50)
Colombia	NR	NR	NR	59 (0.75)	Pituitary	47 (79.7)
Mexico	NR	NR	NR	121 (1.53)	Metastatic	55 (45.5)
<b>MENA</b>						
Algeria	NR	NR	NR	2 (0.03)	None	None
Egypt	481 (1.53)	Unclassified	397 (82.5)	166 (2.1)	Gliomas	60 (36.1)
Iran	NR	NR	NR	1582 (20)	Unclassified	615 (38.9)
Jordan	172 (0.55)	Astrocytic	98 (57)	4 (0.05)	None	None
Lebanon	NR	NR	NR	4 (0.05)	None	None
Libya	NR	NR	NR	1 (0.01)	None	None
Morocco	NR	NR	NR	79 (1)	Astrocytic	34 (43)
Oman	NR	NR	NR	2 (0.03)	None	None
Qatar	NR	NR	NR	2 (0.03)	None	None
Saudi Arabia	281 (0.89)	Astrocytic	116 (41.3)	7 (0.09)	None	None
Tunisia	NR	NR	NR	7 (0.09)	None	None
UAE	NR	NR	NR	4 (0.05)	Cranial & Paraspinal Nerves	2 (50)
<b>SA</b>						
Bangladesh	NR	NR	NR	9 (0.11)	Meningeal	8 (88.9)
India	NR	NR	NR	70 (0.89)	Astrocytic	66 (94.3)
Pakistan	518 (1.64)	Astrocytic	277 (53.5)	376 (4.75)	Pituitary	282 (75)
<b>SSA</b>						
Kenya	NR	NR	NR	26 (0.33)	Unclassified	17 (65.4)
Nigeria	NR	NR	NR	5 (0.06)	None	None
South Africa	NR	NR	NR	4 (0.05)	Embryonal	2 (50)
Total Reported Cases	ALL	31530			7910	
Total Reporting Countries	ALL	21			38	

official websites of cancer registries networks, such as Globocan, AFRN (African Cancer-Registry Network) and EUCAN, or cancer registries for 149 individual countries. For PubMed search, four main limitation steps were applied. The first included year, tumor, incidence and country name, the second involved scanning retrieved abstracts for a list of key words, the third involved checking for authenticity of names (Sometimes a name of country overlapped with other elements for example the name Georgia stands for a European developing country and an American state) and finally a check on the date of the reported cases was applied (some papers were published in 2010 but were reporting cases prior to 2009).

### Data analysis

Identified reported cases were fitted within 17 WHO classified groups (Louis et al., 2007) based on descriptive names by source. Grouped tumors for reported names included: astrocytic tumors [reported names were pilocytic astrocytoma, pilomyxoid astrocytoma, diffuse astrocytoma, fibrillary astrocytoma, anaplastic astrocytoma, gbm, gliosarcoma, and sega], meningeal tumors [reported names were meningioma, atypical meningioma, haemangiopericytoma and haemangioblastoma], oligodendroglial tumors [reported names were oligodendroglioma and anaplastic oligodendroglioma], embryonal tumors [reported names were embryonal, medulloblastoma, melanotic neuroectodermal tumour of infancy, and atypical teratoid/rhabdoid tumor], oligoastrocytic tumors [reported names were oligoastrocytoma and anaplastic oligoastrocytoma], ependymal tumors [reported names were ependymoma and myxopapillary ependymoma], tumors of cranial and paraspinal nerves [reported names were schwannoma, neurinoma, acoustic neuroma, nerve sheath tumors and spinal neurofibromatosis], other neuroepithelial tumors [reported names were astroblastoma and chordoid glioma], mesenchymal tumors [reported names were chondroma, lipoma, haemangioma, angiolipoma, rhabdomyosarcoma

and ewing sarcoma – pnet], neuronal and mixed neuronal-glioma tumors [reported names were ganglioglioma, neurocytoma and papillary glioneuronal tumors], pineal tumors [reported names were pineoblastoma and other pineal tumors], germ cell tumors [reported names were germ cell, germinoma, yolk sac tumors and teratoma], and choroid plexus tumors [reported names were choroid plexus and choroid plexus papilloma]. tumors reported as “low grade gliomas” or “high grade gliomas” were included as an independent “gliomas” group. Unclassified tumors were also considered as an independent group.

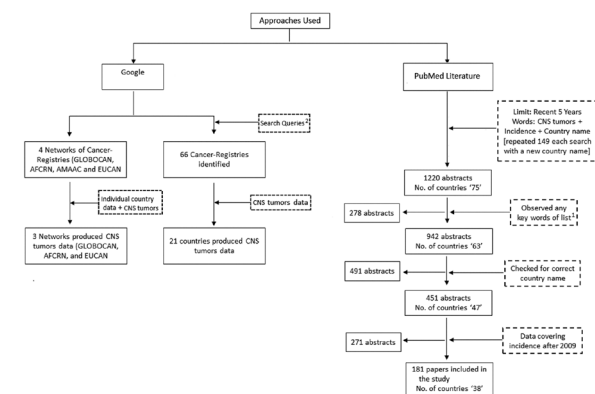
Identified countries were grouped within six regions: Europe and Central Asia (ECA), Latin America and the Caribbean (LAC), East Asia and Pacific (EAP), Middle East and North Africa (MENA), South Asia (SA), and Sub-Saharan Africa (SSA), as per WHO cataloging.

Linear regression analyses for the relationship of Globocan reported incidence ASR (Ln) for all CNS tumors reported from 169 WHO registered countries, or 126 developing countries, verses latitude or longitude were run using SPSS Graduate Pack 16.0. A similar process was applied to test the significance of the relationship between PubMed reported Astrocytic tumors counts (Ln) for 25 countries with latitude or longitude. Natural logs of CNS tumors counts were chosen since values for counts had skewed distributions. For each country, latitude/longitude coordinates were taken from Google Earth 6.0.2. (Google, 2014).

## Results

### Countries reporting CNS tumors

Out of 66 investigated registries, registries for 21 countries provided information related to CNS tumors (Table 1). Unfortunately, this number was even lower for those registries that provided detailed WHO classifications of CNS tumors (Thailand, Egypt, Jordan, Saudi Arabia, Pakistan, and Romania). The total reported cases identified in cancer registries for the years 2009–2012 was 31530, with Russian Federation (7377 cases, 23.4%), Ukraine (7361 cases, 23.3%) and Poland (4467 cases, 14.1%) being the top contributors (Batut, 2009 and 2010; Chiricuta, 2010; NCREgypt, 2010; WHO, 2010; KFSHRC, 2011; CroatianNCR, 2012; EUCAN, 2012; IARC, 2012; NCIThailand, 2012; Piya and Acharya, 2012; SHATOBulgaria, 2012; AFRN, 2013; AMAAC, 2013; MOHJordan, 2013; NCIUkraine, 2013; ShaukatKhanum, 2013). In contrast, 38 countries have reported CNS tumor cases in 181 published papers (Ahmad et al., 2009; Akhaddar et al., 2009; Al-Dahri et al., 2009; Al-Hussain and Dababo, 2009; Ali et al., 2009; Alimohamadi et al., 2009; Alpizar-Aguirre et al., 2009; Awad et al., 2009; Bien et al., 2009; Boongird et al., 2009; Bozic et al., 2009; Charfi et al., 2009; Ciobanu et al., 2009; Conca et al., 2009; Enchev et al., 2009; Ghitou et al., 2009; Gomori et al., 2009; Grahovac et al., 2009; Jamjoom et al., 2009; Joo et al., 2009; Komolafe et al., 2009; Limaem et al., 2009; Liu et al., 2009; Mallea-Gil et al., 2009; Marinovic et al., 2009; Mikati et al., 2009; Mosqueda-Taylor et al., 2009; Naydenov et al., 2009; Olufemi Adeleye and Balogun, 2009; Pronin et al., 2009;



**Figure 1. A Flow Chart for Search Strategy and Data Extraction Approaches Used in this Study.** Dashed-Box (---) represents limitations used for the search. Keywords list1: CNS tumors in [Country name] 149 developing countries, Cancer, Registry, Data, Statistics, Incidence rate, Mortality/death rate, Prevalence, Epidemiology, Registration, Quantitative study, Clinical profile, or ASR. Search Queries2: [Country name] 149 developing countries and Cancer registry or Cancer Society or Cancer report or Cancer statistics

Salih et al., 2009; Sarwat and Al-Salam, 2009; Till et al., 2009; Vega et al., 2009; Alzarar et al., 2010; Arshad et al., 2010; Azarpira et al., 2010; Bankole et al., 2010; Benzagmout et al., 2010; Campos and Linhares, 2010; Chansriwong and Sirisinha, 2010; Dezmalj-Grbelja et al., 2010; Diez et al., 2010; El-Bilbeisi et al., 2010; El Beltagy et al., 2010; Fatehi et al., 2010; Gryngarten et al., 2010; Ishaqi et al., 2010; Jabri et al., 2010; Khawam et al., 2010; Khoddami and Gholampour Shahaboddini, 2010; Lakicevic et al., 2010; Las Heras and Pritzker, 2010; Masroujeh et al., 2010; Mondok et al., 2010; Nasir et al., 2010; Nicolae et al., 2010; Niculescu et al., 2010; Ortiz-Plata et al., 2010; Rizvi et al., 2010; Shamov et al., 2010; Vuckovic et al., 2010; Yaneva et al., 2010; Adeleye and Rabi, 2011; Ajani et al., 2011; Al-Hussaini et al., 2011; Al-Masri et al., 2011; Amirjamshidi et al., 2011; Asmoniene et al., 2011; Ayoub, 2011; Balinisteanu et al., 2011; Binesh et al., 2011; Garcia-Quintanilla et al., 2011; Ghosal et al., 2011; Jakab et al., 2011; Jamebozorgi et al., 2011; Khalatbari et al., 2011a; Khalatbari et al., 2011b; Khan et al., 2011; Kovacs et al., 2011; Maheshwari et al., 2011; Moona and Mehdi, 2011; Muller et al., 2011; Pruksakorn et al., 2011; Qiao et al., 2011; Quadri et al., 2011; Soliman et al., 2011; Soritau et al., 2011; Tomac et al., 2011; Tsekov et al., 2011; Tunon-Pitalua et al., 2011; Vulcani-Freitas et al., 2011; Witoonpanich et al., 2011; Zakrzewska et al., 2011; Zawrocki et al., 2011; Abbasi et al., 2012; Adeleye et al., 2012; Ajler et al., 2012; Akhtar et al., 2012; Albright and Okechi, 2012; Antic et al., 2012; Berindan-Neagoe et al., 2012; Bieza and Krumina, 2012; Binesh et al., 2012; Bochev et al., 2012; Carrasco et al., 2012; Chentli et al., 2012; Chiun et al., 2012; Choudhury et al., 2012; Chowdhury et al., 2012; Cortes-Medina and Guerrero-Rascon, 2012; Coulibaly et al., 2012; Cruz-Roa et al., 2012; Dawood and Cristofanilli, 2012; Deltuva et al., 2012; Dipro et al., 2012; Dizdarevic et al., 2012; Ech-Cherif El Kettani et al., 2012; Eshraghi et al., 2012;

Fedoul and Souirti, 2012; Gamboa-Vignolle et al., 2012; Gee et al., 2012; Gopalakrishnan et al., 2012; Hantous-Zannad et al., 2012; Herrak et al., 2012; Ilker et al., 2012; Khalatbari et al., 2012; Khoshnevisan et al., 2012; Lavrnjic et al., 2012; Macvanski et al., 2012; Malik et al., 2012; Mnejja et al., 2012; Moguchaia et al., 2012; Naydenov et al., 2012a; Naydenov et al., 2012b; Nunez-Farias et al., 2012; Okechi and Albright, 2012; Ortiz et al., 2012a; Ortiz et al., 2012b; Ouni et al., 2012; Pigac et al., 2012; Qi et al., 2012; Ragab et al., 2012; Ren et al., 2012; Romero-Rojas et al., 2012; Saeedinia et al., 2012; Streletz et al., 2012; Svistov et al., 2012; Tanboon et al., 2012; Thota et al., 2012; Todua and Chedia, 2012; Topkan et al., 2012; Zhai et al., 2012; Zhang et al., 2012; Anis et al., 2013; Beizig et al., 2013; Buglyo et al., 2013; Bunevicius et al., 2013a; Bunevicius et al., 2013b; Casas Parera et al., 2013; Cortez-Conradis et al., 2013; Gigineishvili et al., 2013; Hafiz et al., 2013; Hernandez-Martinez et al., 2013; Hilmani et al., 2013; Jaimovich et al., 2013; Jain et al., 2013; Jazayeri et al., 2013; Khalatbari et al., 2013; Khamlichi et al., 2013; Khan et al., 2013; Naidoo et al., 2013; Piyapittayanan et al., 2013; Rabah et al., 2013; Rahman et al., 2013; Romero-Rojas et al., 2013a; Romero-Rojas et al., 2013b; Romero-Rojas et al., 2013c; Saglam et al., 2013; Tuntiyatorn et al., 2013; Yildirim et al., 2013), all of which had papers classifying CNS tumors into WHO classification. However, a fewer cases (7910 cases) were reported in PubMed during the corresponding period. Bulgaria (2781 cases, 35.1%), Iran (1582 cases, 20.0%) and China (685 cases, 8.6%) were the top contributing countries identified in the PubMed search.

#### *Predominant tumor types reported in individual countries*

The most common reported tumor types for each country included in this study were identified, (Table 1). As expected, the majority of countries reported CNS tumors mainly as unclassified in their cancer registries.

**Table 2. Individually Classified CNS Tumor Cases Reported Via Cancer Registries and PubMed Publications**

Types of Reported CNS Tumors	Reported Cases in Cancer Registries		Reported Cases in PubMed	
	Total (%)	Average (STD DEV (+/-))	Total (%)	Average (STD DEV (+/-))
Unclassified CNS Tumors	30311 (96.1)	1443.3 (493.9)	3612 (45.6)	95.0 (67.5)
Astrocytic Tumors	627 (1.99)	29.8 (14.4)	1245 (15.7)	32.7 (15.8)
Pituitary Tumors	NR	NR	792 (10)	20.8 (9)
Meningeal Tumors	100 (0.32)	4.76 (2.51)	544 (6.88)	14.3 (6.88)
Gliomas (Not WHO Classified)	154 (0.49)	7.33 (4.13)	420 (5.31)	11.0 (4.55)
Oligodendroglial Tumors	78 (0.25)	3.71 (2)	355 (4.49)	9.34 (5.74)
Embryonal Tumors	107 (0.34)	5.1 (2.64)	198 (2.5)	5.21 (2.51)
Oligoastrocytic Tumors	NR	NR	191 (2.41)	5.03 (4.47)
Ependymal Tumors	91 (0.29)	4.33 (2.18)	138 (1.74)	3.63 (2.26)
Metastatic Tumors	NR	NR	117 (1.48)	3.08 (1.85)
Tumors of Cranial & Paraspinal Nerves	1 (0)	0.05 (0.05)	82 (1.04)	2.16 (1.19)
Tumors of the Sellar Region	NR	NR	64 (0.81)	1.68 (0.86)
Other Neuroepithelial Tumors	36 (0.11)	1.71 (0.74)	43 (0.54)	1.13 (1.08)
CNS Lymphoma	14 (0.04)	0.67 (0.48)	41 (0.52)	1.08 (0.87)
Mesenchymal Tumors	5 (0.02)	0.24 (0.14)	25 (0.32)	0.66 (0.27)
Neuronal and Mixed Neuronal-glial Tumors	2 (0.01)	0.1 (0.1)	21 (0.27)	0.55 (0.24)
Pineal Tumors	2 (0.01)	0.1 (0.1)	11 (0.14)	0.29 (0.12)
Germ Cell Tumors	NR	NR	8 (0.1)	0.21 (0.08)
Choroid Plexus Tumors	2 (0.01)	0.1 (0.1)	3 (0.04)	0.08 (0.04)
Total	31530 (100)	1501.4 (487)	7910 (100)	208.15 (83.48)

The exceptions for this were Thailand (63 cases, 53.8%), Jordan (98 cases, 57%), Saudi Arabia (116 cases, 41.3%) and Pakistan (277 cases, 53.5%), who reported Astrocytic tumors as the most frequent type. For data recovered from PubMed, Astrocytic tumors predominated Bosnia and Herzegovina (16 cases, 53.3%), Croatia (40 cases, 70.2%), Hungary (14 cases, 42.4%), Morocco (34 cases, 43%) and India (66 cases, 94.3%). Meningeal tumors predominated China (180 cases, 26.3%), Lithuania (117 cases, 33.6%) and Bangladesh (8 cases, 88.9%). Gliomas (Not WHO Classified) tumors were most frequent in Thailand (61 cases, 69.3%), Latvia (45 cases, 100%), and Egypt (60 cases, 36.1%). Pituitary Tumors were the most reported type in Romania (142 cases, 84.5%), Turkey (146 cases, 60.3%), Chile (3 cases, 50%), Colombia (47 cases, 79.7%) and Pakistan (282 cases, 75.0%), while Embryonal tumors were the most published type in Brazil (37 cases, 97.4%) and South Africa (2 cases, 50%) and Ependymal tumors were most common in Poland (39 cases, 53.4%).

#### *CNS tumor cases reported via cancer registries*

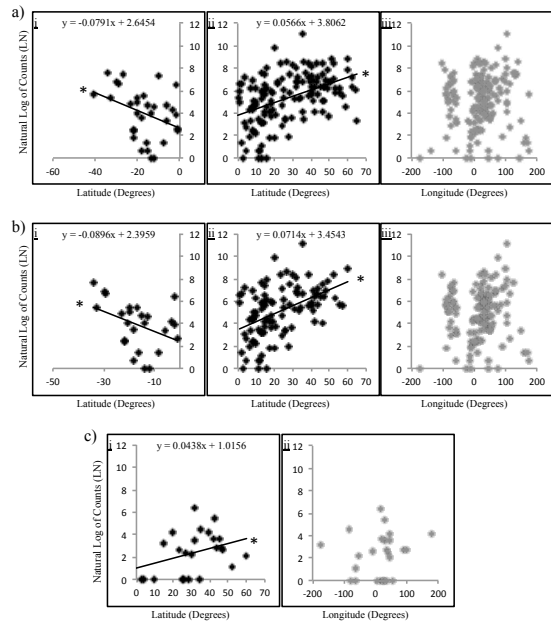
Percentage ordered cases for all reported histopathologically distinguished types of CNS tumors identified through cancer registries showed an overwhelming majority of reported cases to be WHO unclassified (30311 cases, 96.1%), (Table 2). The data for unclassified tumor cases showed a huge variation of reported cases between countries, ranging between a 25-percentile of 77 to a 75-percentile of 2123 and a standard deviation of  $\pm 493.0$ . The top three reported types were astrocytic tumors (627 cases, 1.99%), gliomas (not who classified) (154 cases, 0.49%) and embryonal tumors (107 cases, 0.34%). the least reported types were tumors of cranial and paraspinal nerves (1 case, 0.05%). Only 12 WHO classified categories were noted.

#### *CNS tumor cases reported via pubmed*

For CNS tumor cases identified via PubMed publications 17 WHO CNS tumor categories were noted, (Table 2). Collected data for all tumor cases showed a tighter variation of reported cases between countries ranging between a 25-percentile of 5.3 to a 75-percentile of 155 and a standard deviation of  $\pm 83.48$ . Under half of cases (3612 cases, 45.6%) were unclassified and were labeled as brain and/or CNS tumors. The top three reported types were astrocytic tumors (1245 cases, 15.7%), pituitary tumors (792 cases, 10.0%) and meningeal tumors (544 cases, 6.88%). the least reported types were choroid plexus tumors (3 cases, 0.04%).

#### *Latitude as a possible risk factor for CNS tumors in developing countries*

Several environmental risk factors have been associated with the epidemiology of CNS tumors including ionizing radiation (dental X-rays, CT-scans) (Braganza et al., 2012; Claus et al., 2012; Isaacs, 2013), bisphenol (Zhu et al., 2010), N-nitroso compounds (Huncharek, 2010), pesticides (Searles Nielsen et al., 2010), reproductive hormones (Michaud et al., 2010), JC-virus (Noch et al., 2012), human herpes-viruses (Kofman et al., 2011), and ELF-EMF exposure (Kheifets et al., 2010; Baldi et al.,



**Figure 2. Scatter Blots for the Natural Logs of CNS Tumors Counts Verses Geographical Coordinates of WHO Registered Countries.**

**a)** The natural logs of Globocan reported incidence ASR (Ln) for all CNS tumors from 169 countries versus i) Latitudes of countries south the equator, (-40 to 0°), ii) Latitudes of countries north the equator, (0 to 70°), or iii) Longitudes. **b)** The natural logs of Globocan reported incidence ASR (Ln) for all CNS tumors from 126 developing countries versus i) Latitudes of countries south the equator, (-40 to 0°), ii) Latitudes of countries north the equator, (0 to 70°), or iii) Longitudes. **c)** The natural logs counts of Astrocytic tumor collected from 25 developing countries versus i) Latitudes or ii) Longitudes. Equations for linear regression curves are shown above corresponding blots. The (\*) indicates a significant linear regression relationship

2011). Previous work had shown a association for the occurrence of melanoma (Crocetti et al., 2012), colorectal cancers (Cuomo et al., 2013), lymphoid neoplasms (van Leeuwen et al., 2013) and others (Grant, 2012) with geographical parameters. A linear regression analysis showed a significant relationship between the natural logs of CNS tumors ASR data sourced by Globocan for 169 WHO registered countries and latitudes ranging from -40 till 0 degrees ( $F(2, 32)=4.66, p=0.03$ ) (Figure 2ai), and for latitudes ranging from 0 till 70 degrees ( $F(2, 137)=33.7, p=0.00$ ) (Figure 2a ii). The analysis suggested that the counts of CNS tumor cases increased as the coordinates move away from the equator (Degree 0) in both directions. In contrast, there was no significant relationship observed between the natural logs of CNS tumor incidence ASR of all countries and longitude ( $F(2, 169)=1.04, p=0.30$ ) (Figure 2a iii). A similar pattern was observed for data representing developing countries, where a significant linear regression relationship was observed between the natural logs of CNS tumors ASR data sourced by Globocan for 126 WHO registered developing countries and latitudes ranging from -40 till 0 degrees ( $F(2, 25)=4.40, p=0.04$ ) (Figure 2bi), and for latitudes ranging from 0 till 70 degrees ( $F(2, 101)=27.5, p=0.00$ ) (Figure 2b ii). No significant relationship was observed between the natural logs of CNS tumors ASR

data and longitudes of developing countries (Figure 2biii). Analysis of Astrocytic tumors counts sourced by PubMed showed a comparable pattern (Figure 2c), where natural logs of counts had a significant linear regression relationship with latitudes ranging from 0 till 70 degrees ( $F(2, 25)=5.69, p=0.02$ ), (Figure 2ci). There was no significant relationship between the natural logs of Astrocytic tumor counts and longitude ( $F(2, 25)=0.51, p=0.48$ ) (Figure 2cii).

## Discussion

This study aimed to show epidemiological trends of individually reported CNS tumors subtypes in developing countries. Through a cyber-search approach, it was possible to elucidate trends of frequencies for individually classified CNS tumors and show patterns that were otherwise unavailable. Our data shows that the majority of reported cases from PubMed and cancer registries were for unclassified tumors. For classified tumors, Astrocytic tumors appear to be the most reported type. Interestingly, a relationship between geographical location and the occurrence of CNS tumors may exist.

Unfortunately, out of 149 developing countries only 66 registries representing 21 countries reported any information related to CNS tumors, confirming previous observations for the lack of reporting for CNS tumors in the developing region (Ferlay et al., 2010; Qaddoumi et al., 2011). The degree of reporting for tumors maybe linked to the level of socio-economic development for any particular country. The quality of data collected from the identified registries was poor compared to data retrieved thought published resources. We ensured that included PubMed publications were sourced by clearly individual hospitals or health sectors, and did not produce repetition or overlap of cases. Importantly, data produced from PubMed showed a larger range of tumor classification that was not detected in cancer registries. One problem was the lack of gender or age categorization for declared tumors in publications. Another caveat of retrieving data from such source is the hypothetical bias of results towards research interest in a particular type of tumors. However, our method of selecting published papers was intended to focus on country related data and not any particular tumor classification.

Alarmingly, the majority of reported cases were unclassified (PubMed (45.6%), registries (96.1%)) consistent with the notion that reporting unclassified cancer variants is a growing phenomenon (Tavtigian et al., 2008). This could be a reflection of routed miscommunication between clinicians and statistical departments. It is possible that the epidemiological context for each of these bodies is different. While clinicians and pathologists are more concerned with understanding disease classifications to make crucial decisions involving management of treatment (Tavtigian et al., 2008), reporting statistical departments may be more concerned with “number of cases” in general. In addition, reporting classified tumors is more complex and involves extra documentations, such as pathological reports for classified tumors (Jensen and Storm, 1991). Unfortunately, such vague reporting

systems hamper sharing of detailed medical knowledge and perhaps hinder the development of effective targeted medical management programs.

The retrieved data from PubMed shows that the top three reported types of CNS tumors were Astrocytic tumors, Pituitary tumors and Meningeal tumors. Reasons for the high frequency of Astrocytic tumors are generally not explained (Karipidis et al., 2007). It is possible that since Astrocytic tumors have devastating outcomes with poor survival, more researchers are interested to study them and thus there is more reporting in PubMed, however, Astrocytic tumors were also the most frequently reported type in cancer registries. Another consideration is the complexity of classification for astrocytic tumors, as several different histological categories of variants exist (Wen and Kesari, 2008; Adesina et al., 2010; Karsy et al., 2012) raising the possibility of effect due to increased size of grouping.

Interestingly, when analyzing the relationship between the natural logs of CNS tumors incidence ASR for all WHO registered countries including developing countries verses latitude, or for the natural logs of counts for Astrocytic tumors verses latitude, positive correlations emerged. A similar association has been observed for other tumors (Crocetti et al., 2012; Grant, 2012; Cuomo et al., 2013; van Leeuwen et al., 2013). Latitude effect may be associated with several factors such as UV irradiation, Vitamin D biosynthesis or geographical differences for regional health systems.

In conclusion, reporting epidemiological data for unclassified CNS tumors is a growing phenomenon in the developing world that contradicts the attitude of health professionals to deal with CNS tumors as a collection of independent tumors, of which each requires a targeted health management plan. Unfortunately, Globocan reports treated epidemiological data for CNS tumors within a single category, and only a few cancer registries for developing countries provided information related to the incidences of defined histological CNS tumors types. Through the retrieval of CNS tumor cases using ISI PubMed publications, overall frequencies for individually classified CNS tumors in 38 different countries were elucidated. Patterns associated with frequencies and ranking of classified tumors were deduced as well as novel data implicating an association between individual CNS tumors, such as astrocytic tumors, with geographical location. A consensus for future reporting of CNS tumors incidences need to be established in order to help progress prospects of CNS tumors' health management.

## Acknowledgements

This work is supported by grant HiCi 1434-117-11 issued from the Dean of Scientific Research body in King Abdulaziz University.

## References

- Abbasi A, Azmoudeh Ardalan F, Miri SM, et al (2012). Chondroma of falx: case report of a rare condition. *Acta Med Iran*, **50**, 222-4.

- Adeleye AO, Okolo CA, Akang EE, et al (2012). Cerebral pleomorphic xanthoastrocytoma associated with NF1: an updated review with a rare atypical case from Africa. *Neurosurg Rev*, **35**, 313-9.
- Adeleye AO, Rabiou TB (2011). Foramen magnum meningioma: successful surgical resection in a 76-year-old Nigerian. *Cent Eur Neurosurg*, **72**, 44-5.
- AFCRN. 2013. Current members [Online]. African Cancer Registry Network. Available: <http://afcrn.org/membership/membership-list> [Accessed 10 June 2013].
- Ahmad M, Majid A, Masood M (2009). Intracranial haemangiopericytoma: a very rare entity having a high malignant/metastatic potential. *J Ayub Med Coll Abbottabad*, **21**, 174-6.
- Ajani OA, Al Sulaiti G, Al Bozom I (2011). Pilomyxoid astrocytoma of the cerebellum. *J Neurosurg Pediatr*, **7**, 539-42.
- Ajler P, Goldschmidt E, Bendersky D, et al (2012). Sellar hemangioblastoma mimicking a macroadenoma. *Acta Neurol Taiwan*, **21**, 176-9.
- Akhaddar A, Baite A, Naama O, et al (2009). Hypothalamic lymphoma with symptoms mimicking pituitary apoplexy. *Intern Med*, **48**, 491-2.
- Akhtar MS, Kousar F, Fatmi S, et al (2012). Quality of life and symptoms control in brain metastasis after palliative whole brain radiotherapy using two different protocols. *J Coll Physicians Surg Pak*, **22**, 311-6.
- Al-Dhahri SF, Al-Amro AS, Al-Shakwer W, et al (2009). Cerebellar mass as a primary presentation of papillary thyroid carcinoma: case report and literature review. *Head Neck Oncol*, **1**, 23.
- Al-Hussain TO, Dababo MA (2009). Posterior fossa tumor in a 2 year-old girl. *Brain Pathol*, **19**, 343-6.
- Al-Hussaini M, Abuirmeileh N, Swaidan M, et al (2011). Embryonal tumor with abundant neuropil and true rosettes: a report of three cases of a rare tumor, with an unusual case showing rhabdomyoblastic and melanocytic differentiation. *Neuropathology*, **31**, 620-5.
- Al-Masri AA, Khasawneh NH, Aladily TN (2011). Unusual anatomic location of a primary intracranial yolk sac tumor. *Ann Saudi Med*, **31**, 298-300.
- Albright AL, Okechi H (2012). Use of the NICO myriad device for tumor and cyst removals in a developing country. *Childs Nerv Syst*, **28**, 599-604.
- Ali Y, Rahme R, Moussa R, et al (2009). Multifocal meningeal melanocytoma: a new pathological entity or the result of leptomeningeal seeding? *J Neurosurg*, **111**, 488-91.
- Alimohamadi M, Bidabadi MS, Ayan Z, et al (2009). Pilomyxoid astrocytoma with involvement of the sella turcica in an adolescent. *J Clin Neurosci*, **16**, 1648-9.
- Alpizar-Aguirre A, Zarate-Kalfopulos B, Rosales-Olivares LM, et al (2009). Vertebral hemangioma of the posterior arch with subsequent intraosseous extension and neurological symptoms. Case report and literature review. *Cir Cir*, **77**, 127-30 (in Spanish).
- Alzarae AH, Hussein MR, Amri D, et al (2010). Primary meningioma of the nasal septum: a case report and review of literature. *Appl Immunohistochem Mol Morphol*, **18**, 296-8.
- AMAAC. 2013. Cancer registries [Online]. Arab medical association against cancer (AMAAC). Available: <http://amaac.org/09.htm> [Accessed 20 May 2013].
- Amirjamshidi A, Amiri RS, Alimohamadi M, et al (2011). Concomitant intraventricular colloid cyst and low-grade astrocytoma of the brainstem in a 16-year-old boy. *J Neurosurg Pediatr*, **8**, 342-5.
- Anis KH, Sossa DE, Sossa DG, et al (2013). Intracellular fat graft gains weight with the patient: imaging features. *Neuroradiol J*, **26**, 301-3.
- Antic D, Smiljanic M, Bila J, et al (2012). Hypothalamic dysfunction in a patient with primary lymphoma of the central nervous system. *Neurol Sci*, **33**, 387-90.
- Arshad H, Ahmad Z, Hasan SH (2010). Gliomas: correlation of histologic grade, Ki67 and p53 expression with patient survival. *Asian Pac J Cancer Prev*, **11**, 1637-40.
- Asmoniene V, Skiriute D, Gudiniaviciene I, et al (2011). A primary primitive neuroectodermal tumor of the central nervous system in a 51-year-old woman: a case report and literature review. *Medicina (Kaunas)*, **47**, 440-5.
- Awad IA, El-Kholi NM, El-Lithy MA, et al (2009). Transition from 2D conventional to 3d conformal radiation therapy in patients with brain gliomas: clinical outcome (Mansoura University). *J Egypt Natl Canc Inst*, **21**, 133-8.
- Ayoub B (2011). The far lateral approach for intra-dural anteriorly situated tumours at the craniovertebral junction. *Turk Neurosurg*, **21**, 494-8.
- Azarpira N, Rakei M, Mokhtari M (2010). Cytologic findings in malignant ependymoma: a case report. *Acta Cytol*, **54**, 1023-6.
- Baldi I, Coureau G, Jaffre A, et al (2011). Occupational and residential exposure to electromagnetic fields and risk of brain tumors in adults: a case-control study in Gironde, France. *Int J Cancer*, **129**, 1477-84.
- Balinisteanu B, Ceausu RA, Cimpean AM, et al (2011). Conventional examination versus immunohistochemistry in the prediction of hormone profile of pituitary adenomas. An analysis on 142 cases. *Rom J Morphol Embryol*, **52**, 1041-5.
- Bankole OB, Ojo OA, Kanu OO, et al (2010). Choroid plexus papilloma in a Nigerian child: a case report. *Niger Postgrad Med J*, **17**, 233-6.
- Batut MJ. 2009 and 2010. Cancer incidence and mortality in central serbia [Online]. Institute of Public Health of Serbia. Available: <http://www.batut.org.rs/download/publikacije/Registar%20za%20rak%20u%20Centralnoj%20Srbiji%202010.pdf> [Accessed 10 June 2013].
- Beizig N, Ziadi S, Ladib M, et al (2013). Cerebellar liponeurocytoma: case report. *Neurochirurgie*, **59**, 39-42.
- Benzagmout M, Azzal F, Bitar A, et al (2010). Cervical spinal extradural meningioma: Case report. *Neurochirurgie*, **56**, 401-3.
- Berindan-Neagoe I, Chiorean R, Braicu C, et al (2012). Quantitative mRNA expression of genes involved in angiogenesis, coagulation and inflammation in multiforme glioblastoma tumoral tissue versus peritumoral brain tissue: lack of correlation with clinical data. *Eur Cytokine Netw*, **23**, 45-55.
- Bien E, Stachowicz-Stencel T, Szalewska M, et al (2009). Poor-risk high-grade gliomas in three survivors of childhood acute lymphoblastic leukaemia--an overview of causative factors and possible therapeutic options. *Childs Nerv Syst*, **25**, 619-26.
- Bieza A, Krumina G (2012). Magnetic resonance study on fractional anisotropy and neuronal metabolite ratios in peritumoral area of cerebral gliomas. *Medicina*, **48**, 497-506.
- Binesh F, Akhavan A, Navabii H (2012). Pleomorphic xanthoastrocytoma with malignant transformation and multiple recurrences in an Iranian girl. *BMJ Case Rep*, **2012**.
- Binesh F, Akhavan A, Navabii H, et al (2011). Anaplastic astroblastoma: a rare glial tumour. *BMJ Case Rep*, **2011**.
- Bochev P, Klisarova A, Kaprelyan A, et al (2012). Brain metastases detectability of routine whole body (18)F-FDG PET and low dose CT scanning in 2502 asymptomatic patients with solid extracranial tumors. *Hell J Nucl Med*, **15**, 125-9.
- Boongird A, Laothamatas J, Larbcharoensub N, et al (2009).

- Malignant craniopharyngioma; case report and review of the literature. *Neuropathol*, **29**, 591-6.
- Bozic B, Rotim K, Kogler A, et al (2009). Cerebellar glioblastoma in the elderly--case report. *Acta Clin Croat*, **48**, 175-8.
- Braganza MZ, Kitahara CM, Berrington de Gonzalez A, et al (2012). Ionizing radiation and the risk of brain and central nervous system tumors: a systematic review. *Neuro Oncol*, **14**, 1316-24.
- BrainTumourFoundation C. 2013. Brain Tumour Facts [Online]. Brain Tumour Foundation of Canada. Available: <http://www.braintumour.ca/2494/brain-tumour-facts> [Accessed 24 Sept 2013].
- Buglyo G, Mehes G, Vargha G, et al (2013). WT1 microdeletion and slowly progressing focal glomerulosclerosis in a patient with male pseudohermaphroditism, childhood leukemia, Wilms tumor and cerebellar angioblastoma. *Clin Nephrol*, **79**, 414-8.
- Bunevicius A, Deltuva V, Tamasauskas S, et al (2013a). Screening for psychological distress in neurosurgical brain tumor patients using the patient health questionnaire-2. *Psychooncol*, **22**, 1895-900.
- Bunevicius A, Deltuva V, Tamasauskas S, et al (2013b). Low triiodothyronine syndrome as a predictor of poor outcomes in patients undergoing brain tumor surgery: a pilot study: clinical article. *J Neurosurg*, **118**, 1279-87.
- Campos WK, Linhares MN (2010). Sporadic intramedullary spinal cord hemangioblastoma in a newborn. *Pediatr Neurosurg*, **46**, 385-9.
- CancerResearchUK. 2013a. Brain, other CNS and intracranial tumour statistics [Online]. cancer research UK. Available: <http://www.cancerresearchuk.org/cancer-info/cancerstats/types/brain/> [Accessed 24 Sept 2013].
- CancerResearchUK. 2013b. Brain, other CNS and intracranial tumours incidence statistics [Online]. cancer research UK. Available: <http://www.cancerresearchuk.org/cancer-info/cancerstats/types/brain/incidence/> [Accessed 24 Sept 2013].
- Carrasco CA, Rojas ZD, Chiorino R, et al (2012). Primary pituitary lymphoma in immunocompetent patient: diagnostic problems and prolonged follow-up. *Pituitary*, **15**, 93-6.
- Casas Parera I, Igrio Gamero JL, Blumenkrantz Y, et al (2013). [Utility of 11C-methionine PET/CT in neuro-oncology]. *Medicina (B Aires)*, **73**, 201-6.
- Chansriwong P, Sirisinha T (2010). Clinical features, management and outcomes of high-grade glioma patients in Ramathibodi Hospital. *J Med Assoc Thai*, **93**, 68-73.
- Charfi S, Ayadi L, Khabir A, et al (2009). Gliosarcoma with osteosarcomatous features: a short illustrated review. *Acta Neurochir*, **151**, 809-13.
- Chauvin P, Josselin JM, Heresbach D (2012). Incremental net benefit and acceptability of alternative health policies: a case study of mass screening for colorectal cancer. *Eur J Health Econ*, **13**, 237-50.
- Chentli F, Belhimer F, Kessaci F, et al (2012). Congenital craniopharyngioma: a case report and literature review. *J Pediatr Endocrinol Metab*, **25**, 1181-3.
- Chiricuta I. 2010. Cluj Regional Cancer Registry [Online]. The Oncology Institute. Available: <http://www.ioen.ro/en/Cancer-prevention-and-control-center/Regional-Cancer-Registry/CancerinNorthWesternRegion2009.html> [Accessed 10 June 2013].
- Chiun KC, Tang IP, Vikneswaran T, et al (2012). Intrasellar craniopharyngioma of the posterior nasal septum: a rare entity. *Med J Malaysia*, **67**, 131-2.
- Choudhury T, Jahan S, Kamal M, et al (2012). Von Hippel-Lindau disease in a pregnant lady. *Mymensingh Med J*, **21**, 184-7.
- Chowdhury FH, Haque MR, Goel AH, et al (2012). Endoscopic endonasal extended transsphenoidal removal of tuberculum sellae meningioma (TSM): an experience of six cases. *Br J Neurosurg*, **26**, 692-9.
- Ciobanu AM, Lisievici MG, Coman TC, et al (2009). Giant wing sphenoid meningioma with principal manifestation depression. *Rom J Morphol Embryol*, **50**, 713-7.
- Claus EB, Calvocoressi L, Bondy ML, et al (2012). Dental x-rays and risk of meningioma. *Cancer*, **118**, 4530-7.
- Conca W, Al-Hakim M, Moussa N, et al (2009). Hyperferritinemia in a woman with systemic lupus erythematosus, severe nephritis and an iron-rich intraspinal schwannoma mimicking lupus myelopathy. *Clin Exp Rheumatol*, **27**, 834-7.
- Cortes-Medina JC, Guerrero-Rascon CA (2012). Unusual clinical presentation of astrocytoma in an adult. *Cir Cir*, **80**, 177-81.
- Cortez-Conradis D, Favila R, Isaac-Olive K, et al (2013). Diagnostic performance of regional DTI-derived tensor metrics in glioblastoma multiforme: simultaneous evaluation of p, q, L, Cl, Cp, Cs, RA, RD, AD, mean diffusivity and fractional anisotropy. *Eur Radiol*, **23**, 1112-21.
- Coulibaly O, El Kacemi I, Fatemi N, et al (2012). Mature posterior fossa teratoma mimicking infratentorial meningioma: a case report. *Neurochirurgie*, **58**, 40-3.
- CroatianNCR. 2012. Croatian national cancer registry - annual report [Online]. Croatian National Institute of Public Health. Available: [http://www.hzjz.hr/cancer/annual\\_rep.htm](http://www.hzjz.hr/cancer/annual_rep.htm) [Accessed 10 June 2013].
- Crocetti E, Buzzoni C, Chiarugi A, et al (2012). Relationship between latitude and melanoma in Italy. *ISRN Oncol*, **2012**, 864680.
- Cruz-Roa A, Gonzalez F, Galaro J, et al (2012). A visual latent semantic approach for automatic analysis and interpretation of anaplastic medulloblastoma virtual slides. *Med Image Comput Assist Interv*, **15**, 157-64.
- Cuomo RE, Mohr SB, Gorham ED, et al (2013). What is the relationship between ultraviolet B and global incidence rates of colorectal cancer? *Dermatoendocrinol*, **5**, 181-5.
- Dawood S, Cristofanilli M (2012). Brain metastasis in breast cancer: last barrier to the cure? *Oncology*, **26**, 664, 6.
- DeAngelis LM (2001). Brain tumors. *N Engl J Med*, **344**, 114-23.
- Deltuva VP, Jurkiene N, Kulakiene I, et al (2012). Introduction of novel semiquantitative evaluation of (99m)Tc-MIBI SPECT before and after treatment of glioma. *Medicina (Kaunas)*, **48**, 15-21.
- Dezmalj-Grbelja L, Bosnjak J, Lovrencic-Huzjan A, et al (2010). Moyamoya disease in a patient with brain tumor: case report. *Acta Clin Croat*, **49**, 459-63.
- Diez BD, Statkevich P, Zhu Y, et al (2010). Evaluation of the exposure equivalence of oral versus intravenous temozolomide. *Cancer Chemother Pharmacol*, **65**, 727-34.
- Dipro S, Al-Otaibi F, Alzahrani A, et al (2012). Turcot syndrome: a synchronous clinical presentation of glioblastoma multiforme and adenocarcinoma of the colon. *Case Rep Oncol Med*, **2012**, 720273.
- Dizdarevic K, Hadzic E, Beculic H (2012). Giant craniopharyngioma: 9-year follow up after stereotactic Yttrium -90 instillation and microsurgical resection. *Med Glas (Zenica)*, **9**, 420-4.
- Dolecek TA, Propp JM, Stroup NE, et al (2012). CBTRUS statistical report: primary brain and central nervous system tumors diagnosed in the United States in 2005-2009. *Neuro Oncol*, **14**, 1-49.
- Ech-Cherif El Kettani N, Melhaoui A, El Hassani MR, et al (2012). A rare localization of meningioma: meningioma of the foramen of Monro. *Neurochirurgie*, **58**, 314-6.
- El-Bilbeisi H, Ghannam M, Nimri CF, et al (2010). Craniopharyngioma in a patient with acromegaly due to a



- pituitary macroadenoma. *Ann Saudi Med*, **30**, 485-8.
- El Beltagy MA, Aggag M, Kamal M (2010). Role of intraoperative ultrasound in resection of pediatric brain tumors. *Childs Nerv Syst*, **26**, 1189-93.
- Enchev Y, Ferdinandov D, Kounin G, et al (2009). Radiation-induced gliomas following radiotherapy for craniopharyngiomas: a case report and review of the literature. *Clin Neurol Neurosurg*, **111**, 591-6.
- Eshraghi H, Andronikou S, Fisher-Jeffes N, et al (2012). Anaplastic clear cell ependymoma of the conus medullaris and cauda equina in a 3-year-old child. *J Pediatr Hematol Oncol*, **34**, 316-7.
- EUCAN. 2012. Cancer of the brain and central nervous system [Online]. IARC, European network of cancer registries. Available: <http://eco.iarc.fr/eucan/Cancer.aspx?Cancer=34> [Accessed 10 June 2013].
- Fatehi F, Basiri K, Mehr GK (2010). Calcified brain metastasis of breast cancer. *Acta Neurol Belg*, **110**, 124-5.
- Fedoul B, Souirti Z (2012). Cerebellar ganglioglioma. *Pan Afr Med J*, **12**, 12.
- Ferlay J, Shin HR, Bray F, et al (2010). Estimates of worldwide burden of cancer in 2008: GLOBOCAN 2008. *Int J Cancer*, **127**, 2893-917.
- Gamboa-Vignolle C, Ferrari-Carballo T, Arrieta O, et al (2012). Whole-brain irradiation with concomitant daily fixed-dose temozolomide for brain metastases treatment: a randomised phase II trial. *Radiother Oncol*, **102**, 187-91.
- Garcia-Quintanilla F, Hernandez-Herrera RJ, Ochoa-Torres M, et al (2011). Pituitary tumor detected prenatally. *Ginecol Obstet Mex*, **79**, 225-9 (in Spanish).
- Gee TS, Ghani AR, Idris B, et al (2012). Case report: a rare case of pediatric conus medullaris glioblastoma multiforme. *Med J Malaysia*, **67**, 438-41.
- Ghitoiu A, Rusu EC, Slavoaca D, et al (2009). A hypertensive patient with multiple intracerebral hemorrhages due to brain metastases. *J Med Life*, **2**, 437-9.
- Ghosal N, Furtado SV, Saikiran NA, et al (2011). Angiolipoma in sellar, suprasellar and parasellar region: report on two new cases and review of literature. *Clin Neuropathol*, **30**, 118-21.
- Gigineishvili D, Shengelia N, Shalashvili G, et al (2013). Primary brain tumour epidemiology in Georgia: first-year results of a population-based study. *J Neurooncol*, **112**, 241-6.
- Gomori E, Halbauer JD, Kasza G, et al (2009). Glioblastoma multiforme with an unusual location and clinical course. *Clin Neuropathol*, **28**, 165-7.
- Google. 2014. Geographic information at your fingertips [Online]. Google. Available: <http://earth.google.com/intl/it/> [Accessed 01 March 2014].
- Gopalakrishnan CV, Dhakoji A, Nair S, et al (2012). A retrospective study of primary cerebellar glioblastoma multiforme in adults. *J Clin Neurosci*, **19**, 1684-8.
- Grahovac G, Tomac D, Lambasa S, et al (2009). Cerebellar glioblastomas: pathophysiology, clinical presentation and management. *Acta Neurochir (Wien)*, **151**, 653-7.
- Grant WB (2012). An ecological study of cancer mortality rates in California, 1950-64, with respect to solar UVB and smoking indices. *Dermatoendocrinol*, **4**, 176-82.
- Gryngarten MG, Braslavsky D, Ballerini MG, et al (2010). Spontaneous ovarian hyperstimulation syndrome caused by a follicle-stimulating hormone-secreting pituitary macroadenoma in an early pubertal girl. *Horm Res Paediatr*, **73**, 293-8.
- Hafiz MG, Rahman MR, Yeamin MB (2013). Intradural intramedullary spinal cord meningioma in a seven years old female child. *Mymensingh Med J*, **22**, 180-5.
- Hantous-Zannad S, Neji H, Zidi A, et al (2012). Posterior mediastinal angiomyxolipoma with spinal canal extension. *Tunis Med*, **90**, 816-8.
- Hernandez-Martinez SJ, De Leija-Portilla JO, Medellin-Sanchez R (2013). Cytologic features during intraoperative assessment of central neurocytoma: a report of three cases and review of the literature. *Acta Cytol*, **57**, 400-5.
- Herrak L, Jahnaoui N, Hammi S, et al (2012). Cerebral metastasis of a "ghost" bronchopulmonary tumor. *Rev Pneumol Clin*, **68**, 243-8.
- Hilmani S, Abidi O, Benrahma H, et al (2013). Clinicopathological features and molecular analysis of primary glioblastomas in Moroccan patients. *J Mol Neurosci*, **49**, 567-73.
- Huncharek M (2010). Maternal intake of N-nitroso compounds from cured meat and the risk of pediatric brain tumors: a review. *J Environ Pathol Toxicol Oncol*, **29**, 245-53.
- IARC. 2012. List of Registries [Online]. International Agency for Research on Cancer, WHO. IACR-Associate. Available: <http://eco.iarc.fr/eureg/LinksList.aspx> [Accessed 02 June 2013].
- Ilker A, Aykut B, Muge H, et al (2012). Primary brain T-cell lymphoma during pregnancy. *J Pak Med Assoc*, **62**, 394-6.
- Isaacs D (2013). Computerised tomographic brain scans increase the risk of brain tumour or leukaemia. *J Paediatr Child Health*, **49**, 502-3.
- Ishaqi MK, Jamil A, Khanani M, et al (2010). Hepatic Sinusoidal Obstruction Syndrome in a child after chemotherapy for medulloblastoma. *J Neurooncol*, **97**, 137-41.
- Jabri HE, Dababo MA, Alkhani AM (2010). Subependymoma of the spine. *Neurosciences*, **15**, 126-8.
- Jaimovich R, Jaimovich SG, Arakaki N, et al (2013). Supratentorial intraventricular solitary schwannoma. Case report and literature review. *Childs Nerv Syst*, **29**, 499-504.
- Jain D, Bhalla S, Mehta VS (2013). 48-year-old woman with a cerebellopontine angle mass. *Brain Pathol*, **23**, 231-2.
- Jakab A, Molnar P, Emri M, et al (2011). Glioma grade assessment by using histogram analysis of diffusion tensor imaging-derived maps. *Neuroradiology*, **53**, 483-91.
- Jamebozorgi K, Borhani Haghghi A, Yousefipour GA, et al (2011). Atypical basal ganglia germ cell tumor presenting as cerebral and brainstem hemiatrophy. *Neurologist*, **17**, 107-8.
- Jamjoom AA, Sharab MA, Jamjoom AB, et al (2009). Rapid evolution of a choroid plexus papilloma in an infant. *Br J Neurosurg*, **23**, 324-5.
- Jazayeri SB, Rahimi-Movaghar V, Shokraneh F, et al (2013). Epidemiology of primary CNS tumors in Iran: a systematic review. *Asian Pac J Cancer Prev*, **14**, 3979-85.
- Jensen OM, Storm HH (1991). Cancer registration: principles and methods. Reporting of results. IARC Sci Publ, 108-25.
- Joo JG, Rigo J, Jr., Sapi Z, et al (2009). Foetal craniopharyngioma diagnosed by prenatal ultrasonography and confirmed by histopathological examination. *Prenat Diagn*, **29**, 160-3.
- Karipidis KK, Benke G, Sim MR, et al (2007). Occupational exposure to low frequency magnetic fields and the risk of low grade and high grade glioma. *Cancer Causes Control*, **18**, 305-13.
- Karsy M, Gelbman M, Shah P, et al (2012). Established and emerging variants of glioblastoma multiforme: review of morphological and molecular features. *Folia Neuropathol*, **50**, 301-21.
- Katchy KC, Mallik AA, Al-Nashmi NM, et al (2011). Intracranial tumors in Kuwait: a 15-year survey. *J Neurooncol*, **104**, 271-7.
- KFSHRC. 2011. Saudi Cancer Registry [Online]. King Faisal Specialist Hospital and Research Centre. Available: <http://www.kfshrc.edu.sa/oncology/files/ncr> [Accessed 20 May 2013].
- Khalatbari MR, Borghei-Razavi H, Moharamzad Y (2011a). Intradiploic orbital roof meningioma with pneumosinus

- dilatans in a child: a case report and review of the literature. *Pediatr Neurosurg*, **47**, 66-71.
- Khalatbari MR, Hamidi M, Moharamzad Y (2011b). Glioblastoma multiforme with very rapid growth and long-term survival in children: report of two cases and review of the literature. *Childs Nerv Syst*, **27**, 1347-52.
- Khalatbari MR, Jalaiekhoo H, Hamidi M, et al (2012). Primary spinal epidural rhabdomyosarcoma: a case report and review of the literature. *Childs Nerv Syst*, **28**, 1977-80.
- Khalatbari MR, Jalaiekhoo H, Hamidi M, et al (2013). Craniospinal dissemination of filum myxopapillary ependymoma following spinal trauma: case report and literature review. *Childs Nerv Syst*, **29**, 149-52.
- Khamlichi AE, Melhaoui A, Arkha Y, et al (2013). Role of gamma knife radiosurgery in the management of pituitary adenomas and craniopharyngiomas. *Acta Neurochir*, **116**, 49-54.
- Khan AN, Sharma R, Khalid S, et al (2011). Palinopsia from a posteriorly placed glioma--an insight into its possible causes. *BMJ Case Rep*, 2011.
- Khan SY, Bhatti KM, Koliyadan SV, et al (2013). Asymptomatic ileal schwannoma presenting as a mesenteric tumour: Case report and review of literature. *Sultan Qaboos Univ Med J*, **13**, E330-3.
- Khawam E, Fahed D, Khatib L (2010). Isolated inferior rectus paresis with falling eye phenomenon of the contralateral eye in a patient with pineal tumor: a case report. *Binocul Vis Strabismus Q*, **25**, 31-6.
- Kheifets L, Ahlbom A, Crespi CM, et al (2010). A pooled analysis of extremely low-frequency magnetic fields and childhood brain tumors. *Am J Epidemiol*, **172**, 752-61.
- Khoddami M, Gholampour Shahaboddini R (2010). Choroid plexus papilloma of the cerebellopontine angle. *Arch Iran Med*, **13**, 552-5.
- Khoshnevisan A, Yekaninejad MS, Ardakani SK, et al (2012). Translation and validation of the EORTC brain cancer module (EORTC QLQ-BN20) for use in Iran. *Health Qual Life Outcomes*, **10**, 54.
- Kofman A, Marcinkiewicz L, Dupart E, et al (2011). The roles of viruses in brain tumor initiation and oncomodulation. *J Neurooncol*, **105**, 451-66.
- Komolafe MA, Sunmonu TA, Oke O (2009). Stroke-like syndrome in a middle aged Nigerian woman with metastatic brain cancer. *West Afr J Med*, **28**, 266-9.
- Kovacs A, Toth L, Glavak C, et al (2011). Integrating functional MRI information into conventional 3D radiotherapy planning of CNS tumors. Is it worth it? *J Neurooncol*, **105**, 629-37.
- Lakicevic G, Splavski B, Brekalo Z (2010). The value of stereotactic biopsy in improving survival and quality of life for malignant brain glioma patients. *Coll Antropol*, **34 Suppl 1**, 93-7.
- Las Heras F, Pritzker KP (2010). Adult variant of atypical teratoid/rhabdoid tumor: immunohistochemical and ultrastructural confirmation of a rare tumor in the sella tursica. *Pathol Res Pract*, **206**, 788-91.
- Lavrnjc S, Macvanski M, Ristic-Balos D, et al (2012). Papillary glioneuronal tumor: unexplored entity. *J Neurol Surg A Cent Eur Neurosurg*, **73**, 224-9.
- Limaief M, Bellil S, Chelly I, et al (2009). Extraventricular neurocytoma in a child mimicking oligodendroglioma: a diagnostic pitfall. *Pathologica*, **101**, 105-7.
- Liu ZX, Liu YS, Yuan XR, et al (2009). Surgical treatment of childhood craniopharyngioma: clinical analysis of 31 cases. *Zhongguo Dang Dai Er Ke Za Zhi*, **11**, 663-5 (in Chinese).
- Louis DN, Ohgaki H, Wiestler OD, et al (2007). The 2007 WHO classification of tumours of the central nervous system. *Acta Neuropathol*, **114**, 97-109.
- MoH Jordan (2013). Cancer incidence in Jordan [Online]. Ministry of Health (MoH). Available: <http://www.moh.gov.jo/MOH/arabic/publications.php> [Accessed 20 May 2013].
- Macvanski M, Ristic-Balos D, Vasic B, et al (2012). Intracranial yolk sac tumor in an adult patient: MRI, diffusion-weighted imaging and 1H MR spectroscopy features. *Vojnosanit Pregl*, **69**, 277-80.
- Maheshwari V, Mehdi G, Varshney M, et al (2011). Intracranial chondroma: a rare entity. *BMJ Case Rep*, 2011.
- Malik MU, Aberle JC, Flitsch J (2012). CSF fistulas after transsphenoidal pituitary surgery--a solved problem? *J Neurol Surg A Cent Eur Neurosurg*, **73**, 275-80.
- Mallea-Gil MS, Cristina C, Perez-Millan MI, et al (2009). Invasive giant prolactinoma with loss of therapeutic response to cabergoline: expression of angiogenic markers. *Endocr Pathol*, **20**, 35-40.
- Marinovic T, Grahovac G, Habek M, et al (2009). Simultaneous conus medullaris ependymoma and cerebellar astrocytoma in the same patient. *Clin Neuropathol*, **28**, 173-6.
- Masroujeh R, Otrocko ZK, Yamout B, et al (2010). Myasthenia gravis developing in a patient with CNS lymphoma. *Int J Hematol*, **91**, 522-4.
- Michaud DS, Gallo V, Schlehofer B, et al (2010). Reproductive factors and exogenous hormone use in relation to risk of glioma and meningioma in a large European cohort study. *Cancer Epidemiol Biomarkers Prev*, **19**, 2562-9.
- Mikati MA, El-Bitar MK, Najjar MW, et al (2009). A child with refractory complex partial seizures, right temporal ganglioglioma, contralateral continuous electrical status epilepticus, and a secondary Landau-Kleffner autistic syndrome. *Epilepsy Behav*, **14**, 411-7.
- Mnejja M, Hammami B, Bougacha L, et al (2012). Primary sinonasal meningioma. *Eur Ann Otorhinolaryngol Head Neck Dis*, **129**, 47-50.
- Moguchaia OV, Shchedrenok VV, Zakhmatov IG, et al (2012). Questions of quality and its assessment in rendering medical aid to patients with cerebral tumors. *Vestn Khir Im I I Grek*, **171**, 91-3 (in Greek).
- Mondok A, Aranyi Z, Kovacs GG, et al (2010). Rapid progression of amyotrophic lateral sclerosis in an acromegalic patient after surgical resection of a growth hormone-producing pituitary adenoma. *Neurologist*, **16**, 315-8.
- Moona MS, Mehdi I (2011). Nasopharyngeal carcinoma presented as cavernous sinus tumour. *J Pak Med Assoc*, **61**, 1235-6.
- Mosqueda-Taylor A, Dominguez-Malagon H, Cano-Valdez AM, et al (2009). Primary extracranial meningioma of the mandible. *Med Oral Patol Oral Cir Bucal*, **14**, 167-70.
- Muller C, Adroos N, Lockhat Z, et al (2011). Tooth craniopharyngioma: a literature review and case report of craniopharyngioma with extensive odontogenic differentiation and tooth formation. *Childs Nerv Syst*, **27**, 323-6.
- Naidoo J, Potgieter L, Wieselthaler N, et al (2013). Melanotic neuroectodermal tumour of infancy, a rare cause for a bump on the head. *Childs Nerv Syst*, **29**, 167-72.
- Nasir S, Jamila B, Khaleeq S (2010). A retrospective study of primary brain tumors in children under 14 years of age at PIMS, Islamabad. *Asian Pac J Cancer Prev*, **11**, 1225-7.
- Naydenov E, Marinov M, Nachev S (2012a). Two different primary brain tumors, glioblastoma multiforme and pituitary adenoma, in association with colorectal carcinoma: an unusual case of nonfamilial Turcot's syndrome? *J Neurol Surg A Cent Eur Neurosurg*, **73**, 410-2.
- Naydenov E, Tzekov C, Minkin K, et al (2009). [Clinical, histopathological and cytogenetical findings in six cases with primary glioblastoma multiforme]. *Khirurgiia*, 49-55.

- Naydenov E, Tzekov C, Minkin K, et al (2012b). Malignant progression of anaplastic supratentorial ganglioglioma into glioblastoma multiforme in a patient with Turner syndrome. *J Neurol Surg A Cent Eur Neurosurg*, **73**, 253-5.
- NCIThailand. 2012. Cancer registry 2002-2010 [Online]. National Cancer Institute of Thailand. Available: [http://www.nci.go.th/en/cancer\\_record/cancer\\_rec1.html](http://www.nci.go.th/en/cancer_record/cancer_rec1.html) [Accessed 05 June 2013].
- NCIUkraine. 2013. Incidence, mortality, activities of oncological service, Bulletin of national cancer registry of Ukraine [Online]. National cancer institute of Ukraine. Available: [http://www.ncru.inf.ua/publications/BULL\\_14/index\\_e.htm](http://www.ncru.inf.ua/publications/BULL_14/index_e.htm) [Accessed 10 June 2013].
- NCREgypt. 2010. Reports and Statistics Accessed [Online]. National Cancer Registry Program of Egypt. Available: <http://www.cancerregistry.gov.eg/reports.aspx> [Accessed 20 May 2013].
- Nicolae L, Iacob G, Poparda M, et al (2010). Case report. Gelastic seizures in a patient with right gyrus cinguli astrocytoma. *J Med Life*, **3**, 433-6.
- Niculescu CE, Stanescu L, Popescu M, et al (2010). Supratentorial pilocytic astrocytoma in children. *Rom J Morphol Embryol*, **51**, 577-80.
- Noch E, Sariyer IK, Gordon J, et al (2012). JC virus T-antigen regulates glucose metabolic pathways in brain tumor cells. *PLoS One*, **7**, 35054.
- Nunez-Farias AC, Borzutzky A, Morales PS, et al (2012). Severe spinal neurofibromatosis in a child. *J Pediatr*, **161**, 368- e1.
- Okechi H, Albright AL (2012). Intraventricular meningioma: case report and literature review. *Pediatr Neurosurg*, **48**, 30-4.
- Olufemi Adeleye A, Balogun JA (2009). Bilateral deafness and blindness from a 14th ventricular medulloblastoma. *Br J Neurosurg*, **23**, 315-7.
- Ortiz-Plata A, Moreno-Leyva K, Lopez-Gomez M, et al (2010). Epithelial cell adhesion molecule expression in pituitary adenomas: an immunohistochemical study. *Ann Diagn Pathol*, **14**, 418-24.
- Ortiz LD, Syro LV, Scheithauer BW, et al (2012a). Anti-VEGF therapy in pituitary carcinoma. *Pituitary*, **15**, 445-9.
- Ortiz LD, Syro LV, Scheithauer BW, et al (2012b). Temozolomide in aggressive pituitary adenomas and carcinomas. *Clinics (Sao Paulo)*, **67**, 119-23.
- Ouni FE, Gaha M, Moulahi H, et al (2012). Infratentorial oligodendroglioma in a child: a case report and review of the literature. *Turk Neurosurg*, **22**, 461-4.
- Parkin DM, Bray F, Ferlay J, et al (2001). Estimating the world cancer burden: Globocan 2000. *Int J Cancer*, **94**, 153-6.
- Pigac B, Dmitrovic B, Maric S, et al (2012). Cathepsin D and its prognostic value in neuroepithelial brain tumors. *Coll Antropol*, **36**, 227-33.
- Piya MK, Acharya SC (2012). Oncology in Nepal. *South Asian J Cancer*, **1**, 5-8.
- Piyapittayanan S, Chawalparit O, Tritakarn SO, et al (2013). Value of diffusion tensor imaging in differentiating high-grade from low-grade gliomas. *J Med Assoc Thai*, **96**, 716-21.
- Pronin IN, McManus KA, Holodny AI, et al (2009). Quantification of dispersion of Gd-DTPA from the initial area of enhancement into the peritumoral zone of edema in brain tumors. *J Neurooncol*, **94**, 399-408.
- Pruksakorn P, Siwanuwatn R, Snabboon T (2011). Spinal hemangioblastoma. *Am J Med Sci*, **342**, 240.
- Qaddoumi I, Unal E, Diez B, et al (2011). Web-based survey of resources for treatment and long-term follow-up for children with brain tumors in developing countries. *Childs Nerv Syst*, **27**, 1957-61.
- Qi ST, Liu Y, Pan J, et al (2012). A radiopathological classification of dural tail sign of meningiomas. *J Neurosurg*, **117**, 645-53.
- Qiao PF, Niu GM, Han XD (2011). Hemangioblastoma originating from the right cerebellopontine angle. *Neurosciences*, **16**, 372-4.
- Quadri SA, Sobani ZA, Enam SA, et al (2011). Primary central nervous system lymphoma causing multiple spinal cord compression and carcinomatous meningitis in a 6-year-old: a case report. *J Pediatr Hematol Oncol*, **33**, 312-5.
- Rabah F, Al-Mashaikhi N, Beshlawi I, et al (2013). Brain is not always the last fortress; osteosarcoma with large brain metastasis. *J Pediatr Hematol Oncol*, **35**, 91-3.
- Ragab A, Emara A, Shouker M, et al (2012). Prospective evaluation of the clinical profile and referral pattern differences of vestibular schwannomas and other cerebellopontine angle tumors. *Otol Neurotol*, **33**, 863-70.
- Rahman A, Hoque SU, Bhandari PB, et al (2013). Contiguous haemangioblastomas of the brain and spine in a patient of Von Hippel-Lindau disease. *BMJ Case Rep*, **2013**.
- Ren X, Cui X, Lin S, et al (2012). Co-deletion of chromosome 1p/19q and IDH1/2 mutation in glioma subsets of brain tumors in Chinese patients. *PLoS One*, **7**, 32764.
- Rizvi S, Asghar AH, Mehboob J (2010). Gliosarcoma: a rare variant of glioblastoma multiforme. *J Pak Med Assoc*, **60**, 773-5.
- Romero-Rojas AE, Diaz-Perez JA, Amaro D, et al (2013a). Glioblastoma metastasis to parotid gland and neck lymph nodes: fine-needle aspiration cytology with histopathologic correlation. *Head Neck Pathol*, **7**, 409-15.
- Romero-Rojas AE, Diaz-Perez JA, Amaro D, et al (2013b). Primary esophageal meningioma: first literature report. *J Clin Gastroenterol*, **47**, 58-61.
- Romero-Rojas AE, Diaz-Perez JA, Ariza-Serrano LM (2012). CD99 is expressed in chordoid glioma and suggests ependymal origin. *Virchows Arch*, **460**, 119-22.
- Romero-Rojas AE, Diaz-Perez JA, Chinchilla-Olaya SI, et al (2013c). Histopathological and immunohistochemical profile in anaplastic gangliogliomas. *Neurocirugia (Astur)*, **24**, 237-43.
- Saeedina S, Nouri M, Alimohammadi M, et al (2012). Primary spinal extradural Ewing's sarcoma (primitive neuroectodermal tumor): Report of a case and meta-analysis of the reported cases in the literature. *Surg Neurol Int*, **3**, 55.
- Saglam A, Akyurek N, Soylemezoglu F, et al (2013). Epstein-Barr virus frequency in primary central nervous system lymphomas in Turkey. *APMIS*, **121**, 232-8.
- Salih SB, Saeed AB, Alzahrani M, et al (2009). Primary CNS lymphoma presenting as fever of unknown origin. *J Neurooncol*, **93**, 401-4.
- Sarwat AM, Al-Salam S (2009). Expression of HIF-1, galectin-3, cox-2 and Wilms tumor-1 protein in multiple schwannomas of the conus medullaris. *J Neurooncol*, **92**, 111-5.
- Searles Nielsen S, McKean-Cowdin R, Farin FM, et al (2010). Childhood brain tumors, residential insecticide exposure, and pesticide metabolism genes. *Environ Health Perspect*, **118**, 144-9.
- Shamov T, Spiriev T, Tzvetanov P, et al (2010). The combination of neuronavigation with transcranial magnetic stimulation for treatment of opercular gliomas of the dominant brain hemisphere. *Clin Neurol Neurosurg*, **112**, 672-7.
- SHATOBulgaria. 2012. Bulgarian National Cancer Registry [Online]. SHATO. Available: <http://www.sbaloncology.bg/en/ncr.html>. [Accessed 10 June 2013].
- Shaukat Khanum (2013). Cancer registry and clinical data management [Online]. Shaukat Khanum Memorial Cancer Hospital and Research Centre. Available: <http://www.shaukatkhanum.org.pk/research/cancer-registry-and-clinical-data-management.html> [Accessed 05 June 2013].

- Soliman RN, Hassan AR, Rashwan AM, et al (2011). Prospective, randomized study to assess the role of dexmedetomidine in patients with supratentorial tumors undergoing craniotomy under general anaesthesia. *Middle East J Anesthesiol*, **21**, 325-34.
- Soritau O, Tomuleasa C, Aldea M, et al (2011). Metformin plus temozolomide-based chemotherapy as adjuvant treatment for WHO grade III and IV malignant gliomas. *J BUON*, **16**, 282-9.
- Streletz LJ, Terzic D, Salem K, et al (2012). CNS lymphoma masquerading as hemorrhagic stroke. *Clin Neurol Neurosurg*, **114**, 262-4.
- Surawicz TS, McCarthy BJ, Kupelian V, et al (1999). Descriptive epidemiology of primary brain and CNS tumors: results from the Central Brain Tumor Registry of the United States, 1990-1994. *Neuro Oncol*, **1**, 14-25.
- Svistov DV, Martynov BV, Kholiavin AI, et al (2012). Surgical resection in combination with stereotaxic cryodestruction in patients with supratentorial gliomas in functionally significant areas of the brain: possibilities of using combined surgical treatment and its results. *Vestn Khir Im I I Grek*, **171**, 11-6 (in Russian).
- Tanboon J, Sitthinamsuwan B, Paruang T, et al (2012). Primary intracranial Ewing sarcoma with an unusually aggressive course: a case report and review of the literature. *Neuropathology*, **32**, 293-300.
- Tavtigian SV, Greenblatt MS, Goldgar DE, et al (2008). Assessing pathogenicity: overview of results from the IARC Unclassified Genetic Variants Working Group. *Hum Mutat*, **29**, 1261-4.
- Thota B, Shukla SK, Srividya MR, et al (2012). IDH1 mutations in diffusely infiltrating astrocytomas: grade specificity, association with protein expression, and clinical relevance. *Am J Clin Pathol*, **138**, 177-84.
- Till V, Koprivsek K, Stojanovic S, et al (2009). Transient cortical blindness following vertebral angiography in a young adult with cerebellar haemangioblastoma. *Pediatr Radiol*, **39**, 1223-6.
- Todua F, Chedia S (2012). Differentiation between benign and malignant meningiomas using diffusion and perfusion MR imaging. *Georgian Med News*, 16-22.
- Tomac D, Chudy D, Lambasa S, et al (2011). Extracranial propagation of glioblastoma with extension to pterygomaxillary fossa. *World J Surg Oncol*, **9**, 53.
- Topkan E, Topuk S, Oymak E, et al (2012). Pseudoprogression in patients with glioblastoma multiforme after concurrent radiotherapy and temozolomide. *Am J Clin Oncol*, **35**, 284-9.
- Tsekov I, Ferdinandov D, Bussarsky V, et al (2011). Prevalence of JC polyomavirus genomic sequences from the large T-antigen and non-coding control regions among Bulgarian patients with primary brain tumors. *J Med Virol*, **83**, 1608-13.
- Tunon-Pitalua MC, Molina-Olier O, Alcalá-Cerra G, et al (2011). [Intra-spinal clear cell meningioma. Case report and literature review]. *Neurocirugia*, **22**, 50-5.
- Tuntiyatorn L, Nantawas B, Sirachainan N, et al (2013). Apparent diffusion coefficients in evaluation of pediatric brain tumors. *J Med Assoc Thai*, **96**, 178-84.
- van Leeuwen MT, Turner JJ, Falster MO, et al (2013). Latitude gradients for lymphoid neoplasm subtypes in Australia support an association with ultraviolet radiation exposure. *Int J Cancer*, **133**, 944-51.
- Vega J, Goecke H, Carrasco A, et al (2009). [Hyponatremia associated to pituitary adenomas. Report of three patients]. *Rev Med Chil*, **137**, 1607-12.
- Villano JL, Parker CK, Dolecek TA (2013). Descriptive epidemiology of ependymal tumours in the United States. *Br J Cancer*, **108**, 2367-71.
- Vuckovic N, Kozic D, Vulekovic P, et al (2010). MR and MRS characteristics of intraventricular meningioma. *J Neuroimaging*, **20**, 294-6.
- Vulcani-Freitas TM, Saba-Silva N, Cappellano A, et al (2011). ASPM gene expression in medulloblastoma. *Childs Nerv Syst*, **27**, 71-4.
- Wen PY, Kesari S (2008). Malignant gliomas in adults. *N Engl J Med*, **359**, 492-507.
- WHO. 2010. Estimated cancer Incidence, Mortality, Prevalence and Disability-adjusted life years (DALYs) Worldwide in 2008 [Online]. IARC, WHO. Available: <http://globocan.iarc.fr/> [Accessed 15 May 2013].
- Witoonpanich P, Bamrungrak K, Jinawath A, et al (2011). Glioblastoma multiforme at the corpus callosum with spinal leptomeningeal metastasis. *Clin Neurol Neurosurg*, **113**, 407-10.
- Woehrer A (2013). Brain tumor epidemiology in Austria and the Austrian Brain Tumor Registry. *Clin Neuropathol*, **32**, 269-85.
- Yaneva MP, Semerdjieva ML, Radev LR, et al (2010). Postoperative chemo-radiotherapy with temodal in patients with glioblastoma multiforme--survival rates and prognostic factors. *Folia Med*, **52**, 26-33.
- Yildirim AE, Divanlioglu D, Nacar OA, et al (2013). Incidence, hormonal distribution and postoperative follow up of atypical pituitary adenomas. *Turk Neurosurg*, **23**, 226-31.
- Zakrzewska M, Zakrzewski K, Gresner SM, et al (2011). Polycomb genes expression as a predictor of poor clinical outcome in children with medulloblastoma. *Childs Nerv Syst*, **27**, 79-86.
- Zawrocki A, Izycka-Swieszewska E, Papierz W, et al (2011). Analysis of the prognostic significance of selected morphological and immunohistochemical markers in ependymomas, with literature review. *Folia Neuropathol*, **49**, 94-102.
- Zhai X, Wang J, Zhang J, et al (2012). Comparison of two regimens of postoperative concurrent chemoradiotherapy in adult patients with grade III-IV cerebral gliomas. *Nan Fang Yi Ke Da Xue Xue Bao*, **32**, 255-7 (in Chinese).
- Zhang H, Dong L, Huang Y, et al (2012). Primary intracranial leiomyosarcoma: review of the literature and presentation of a case. *Onkologie*, **35**, 609-16.
- Zhu H, Zheng J, Xiao X, et al (2010). Environmental endocrine disruptors promote invasion and metastasis of SK-N-SH human neuroblastoma cells. *Oncol Rep*, **23**, 129-39.